

Aerobic vaginitis: prevalence, management and outcomes in a large integrated sexual health clinic.

Mark Mason¹

Bethan Little²

Andrew Winter¹



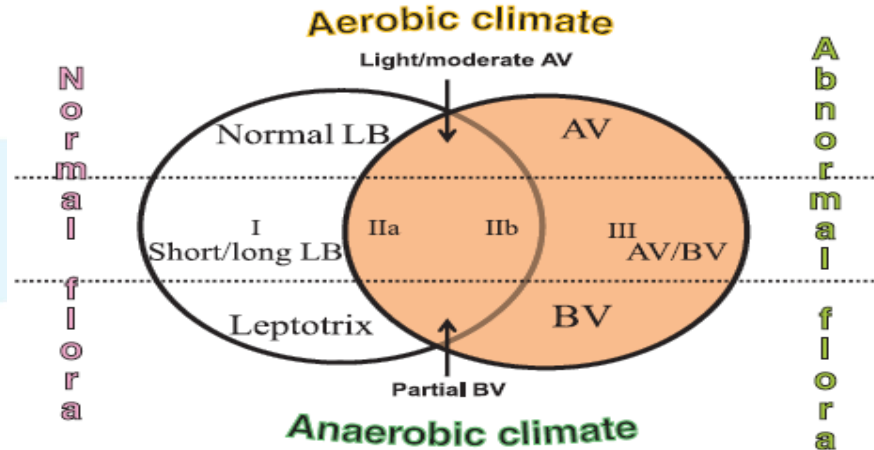
University
of Glasgow

¹*Sandyford Sexual Health Services*

²*University of Glasgow Medical School*

What is aerobic vaginitis?

“Disruption of the lactobacillary flora, accompanied by signs of inflammation and the presence of ... predominantly aerobic microflora composed of enteric commensals or pathogens.”



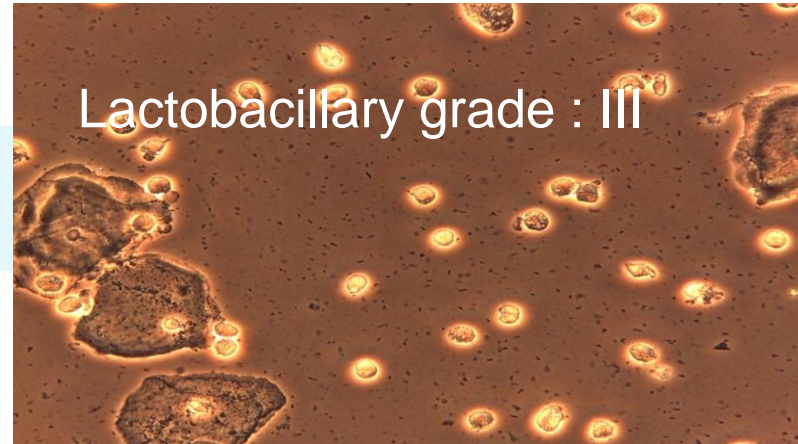
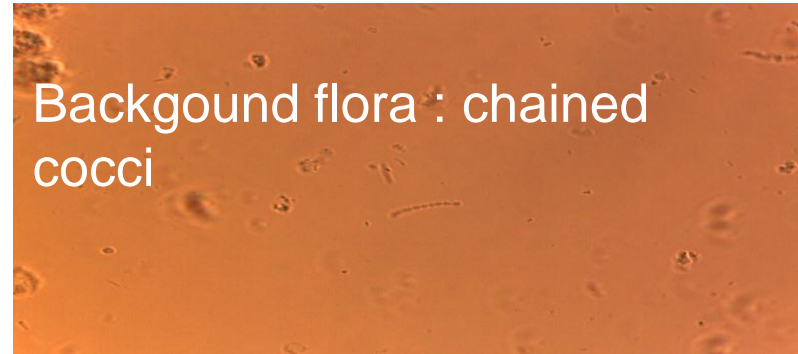
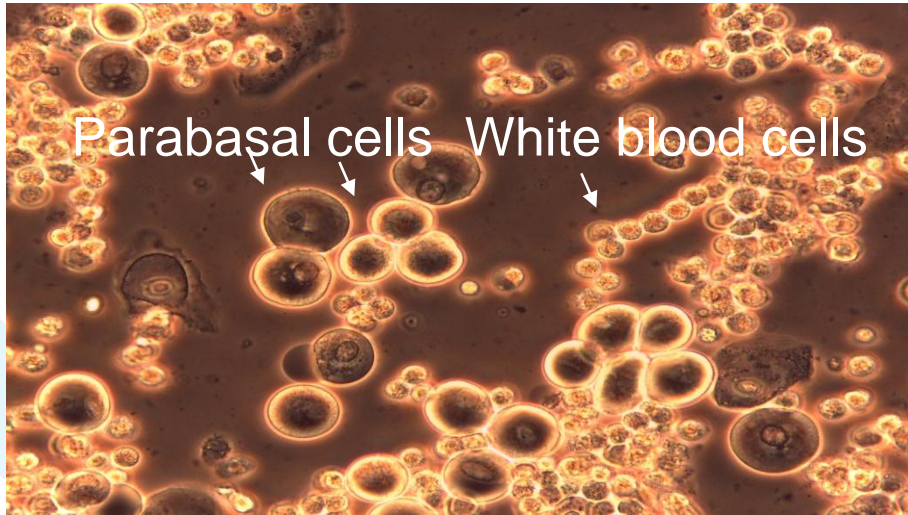AV score

AV Score	Lactobacillary Grades	Number of Leukocytes	Proportion of Toxic Leukocytes	Background Flora	Proportion of Parabasal Epithelium
0	I and IIa	<10/hpf	None/ sporadic	Unremarkable/cytol ysis	None
1	IIb	>10/hpf, <10/epithelial cell	≤ 50% leukocytes	Small coliform bacilli	< or equal 10%
2	III	>10/epithelial cell	>50% leukocytes	Cocci or chains	More than 10%

Total score :

<3 normal
3-4 mild
5-6 moderate
7-10 severe

AV score elements



Sandyford Sexual Health Services

- 110,000 attendances /yr
- Fully integrated 'walk-in' sexual health service
 - Satellite laboratory for near-patient microscopy (approx 200 women/mth)
- Local guidelines suggest syndromic management with referral to us for women with recurrent discharge

Methods

(Nov 2013 to Dec 2014)

- All women who met local criteria for speculum examination and near-patient microscopy.
- Gram stain (Hay-Ison) + wet film (TV).
- Single Biomedical Scientist also scored the wet film slide for AV.¹ Scores of 5 or more alerted to the Clinician.
- Case note review to determine treatment choice and outcome.

¹Definition of a type of abnormal vaginal flora that is distinct from bacterial vaginosis: aerobic vaginitis. BJOG 2002;109:34–43.)

Modified Hay-Ison scoring

Grade	Finding
0	Epithelial cells with no bacteria seen
I	Normal flora (lactobacillus morphotype only)
II	Intermediate (reduced lactos with mixed bacterial morphotype)
III	BV (mixed flora with few or absent lactos)
IV	Epithelial cells covered in Gram+ve cocci

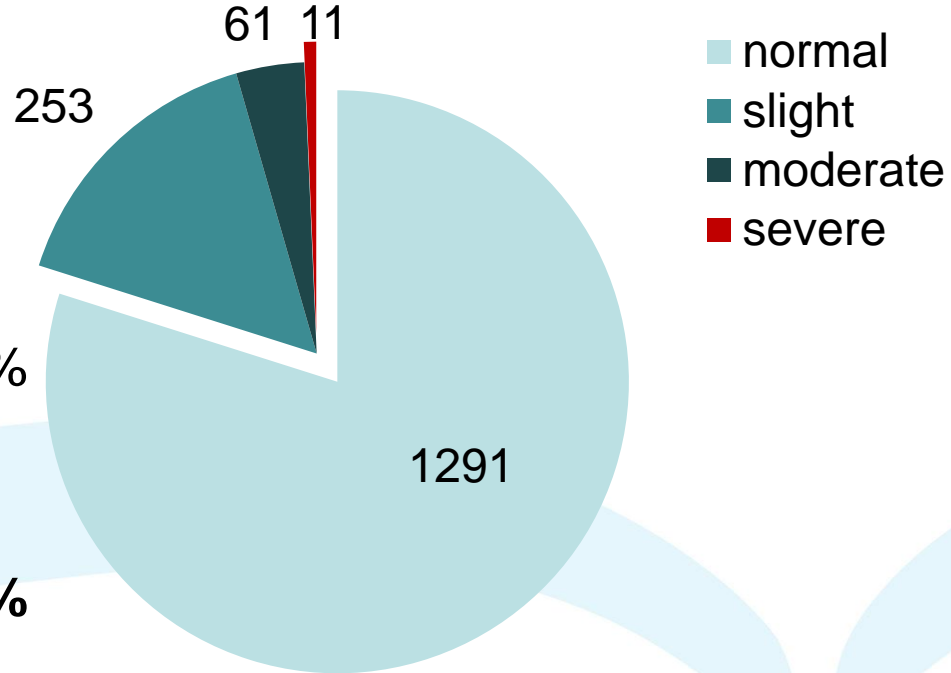
Example Case

- Age 31
 - IBS
 - Irritation and discharge
 - Exam: purulent discharge
 - Microscopy: WBC+++ , abnormal flora includes GPC+++
 - (ie Hay-Ison Grade III ?IV)
- Rx: clindamycin cream 1 week
- HVS: Group B Strep, mixed anaerobes
- Outcome: resolved

AV score = 9 (severe)

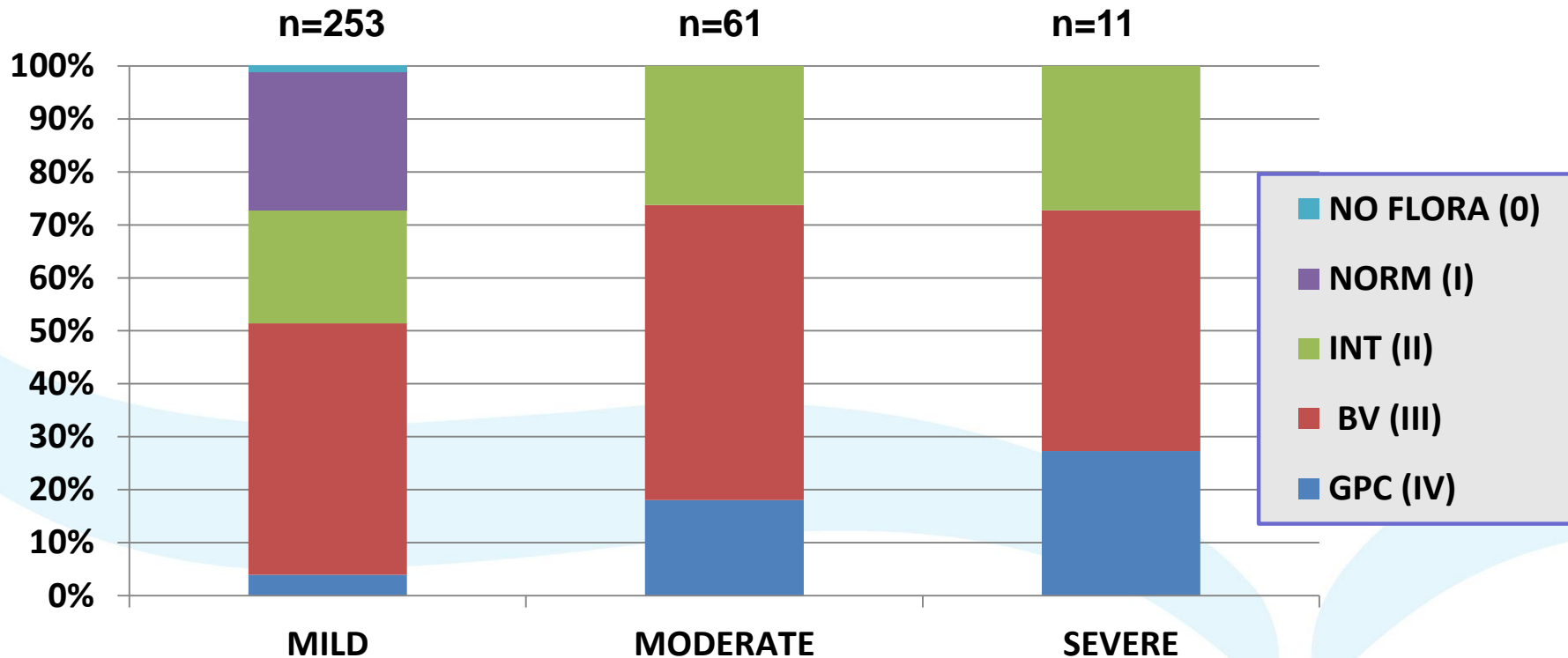
Prevalence of aerobic vaginitis

n=1616

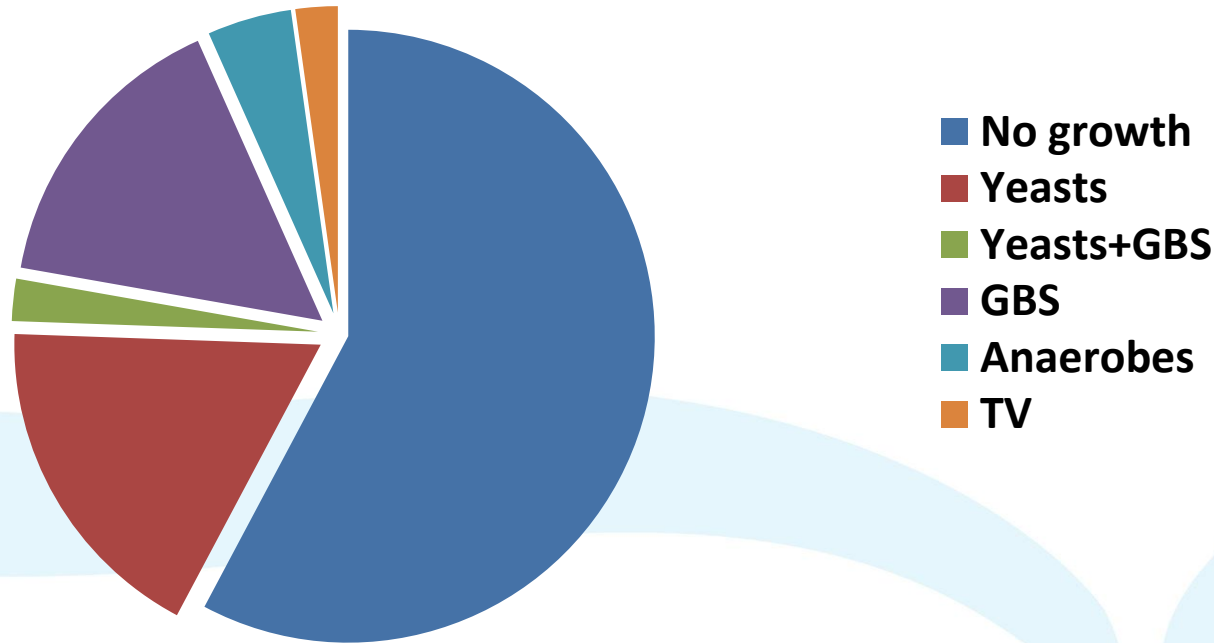


Slight (3-4) : 15.7%
Moderate (5-6) : 3.8%
Severe (>6): 0.7%
Total: 20.2%

Hay-Ison grade vs AV score

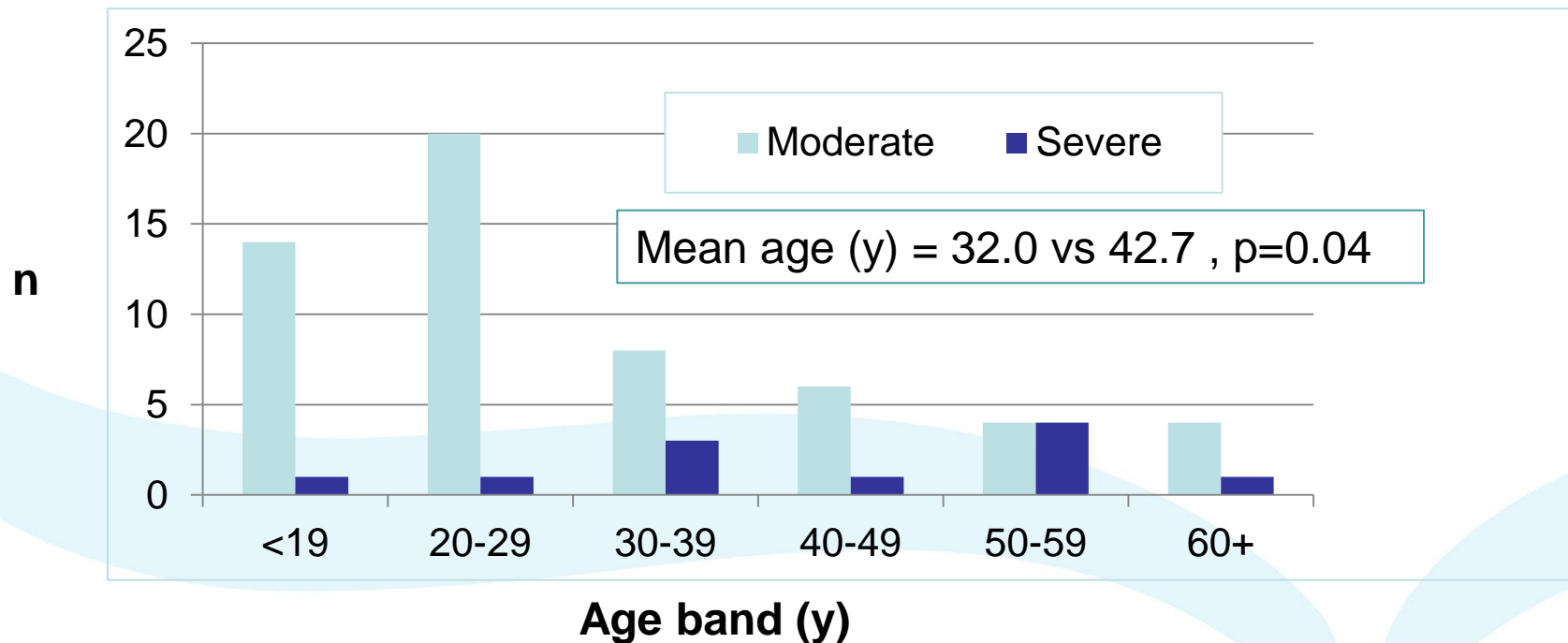


Culture results

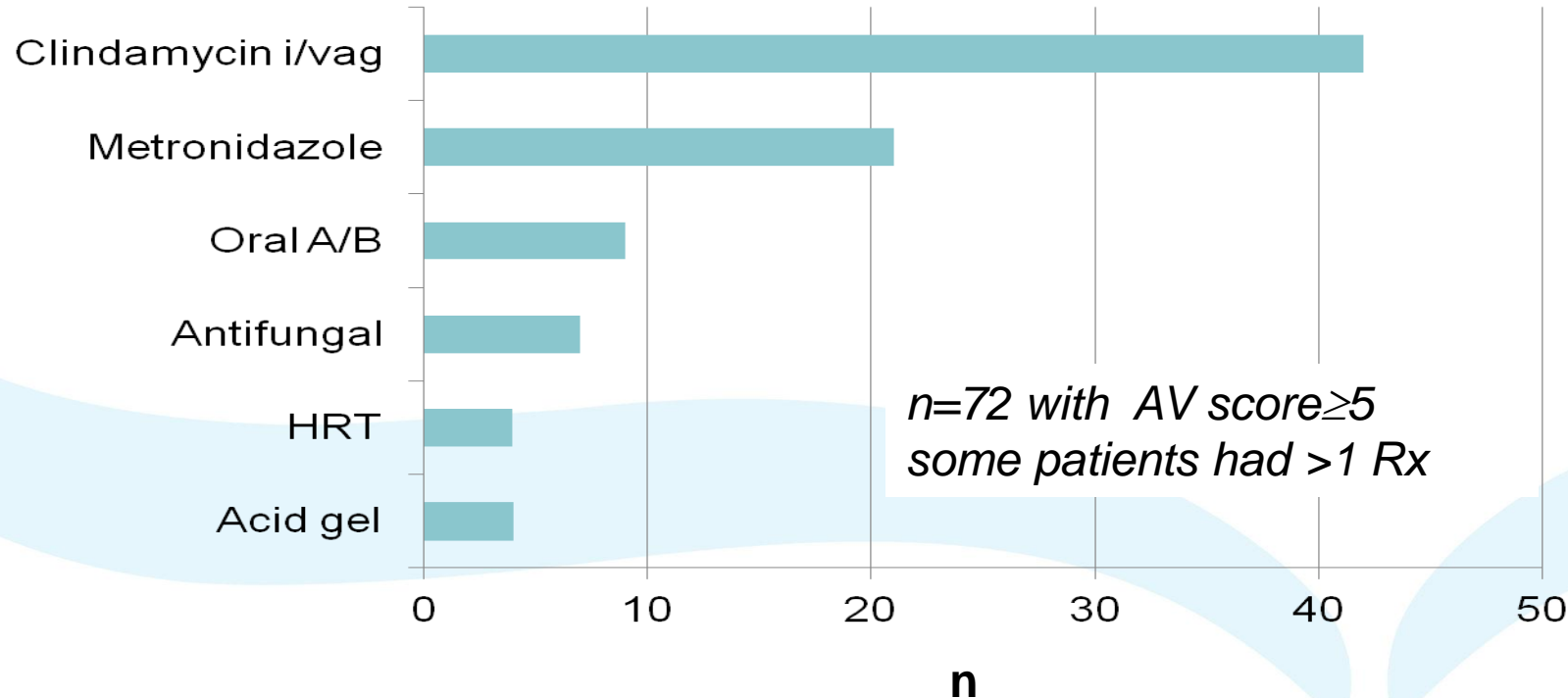


n=45 cultures in women with AV score ≥ 5

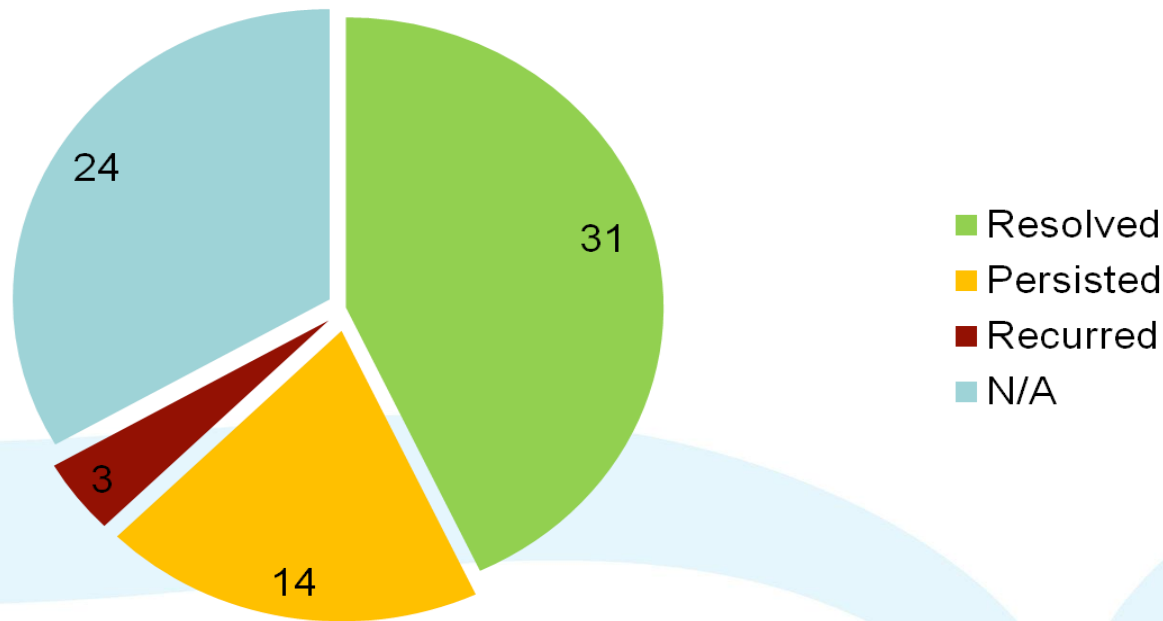
Severe AV affects older population



Treatment choice

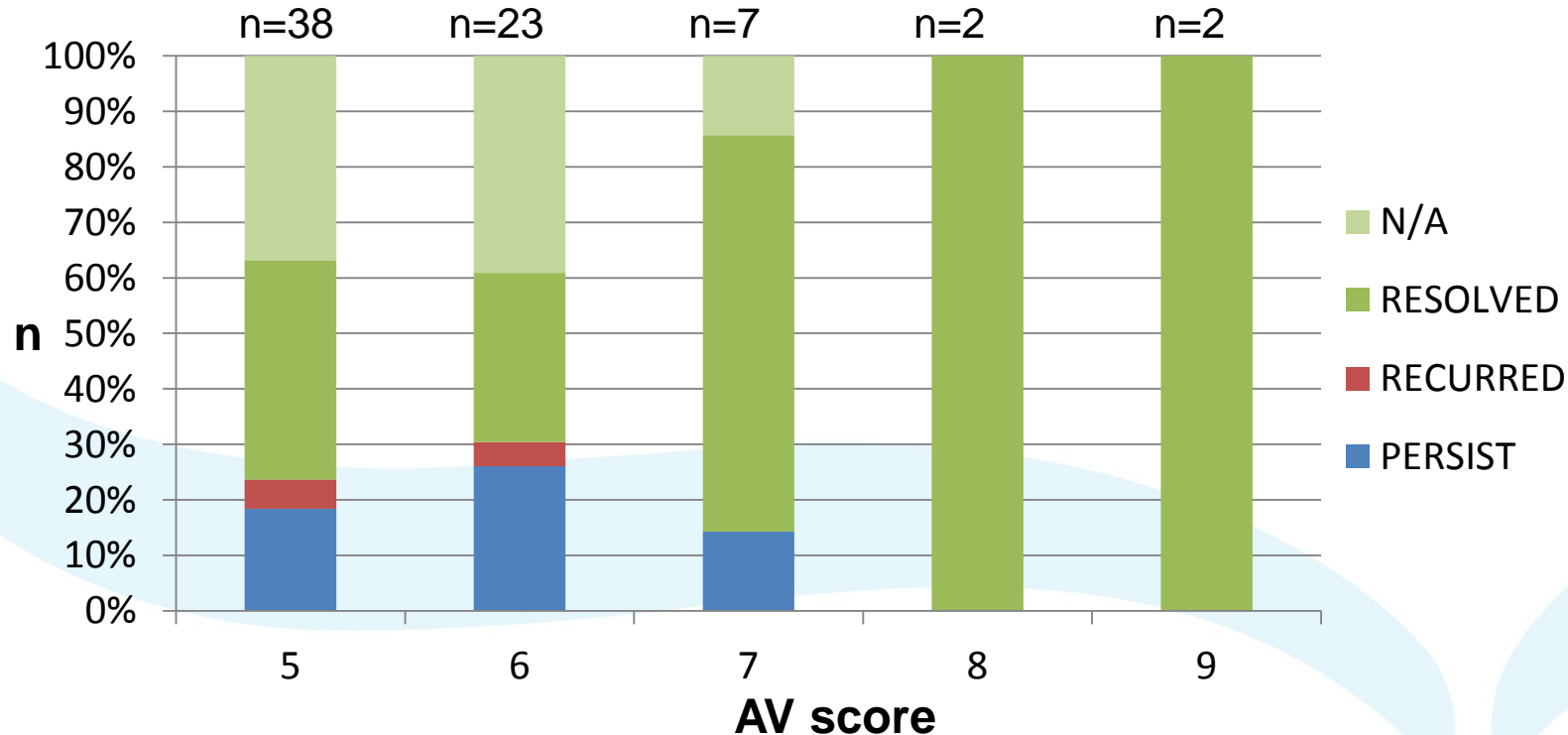


Outcomes

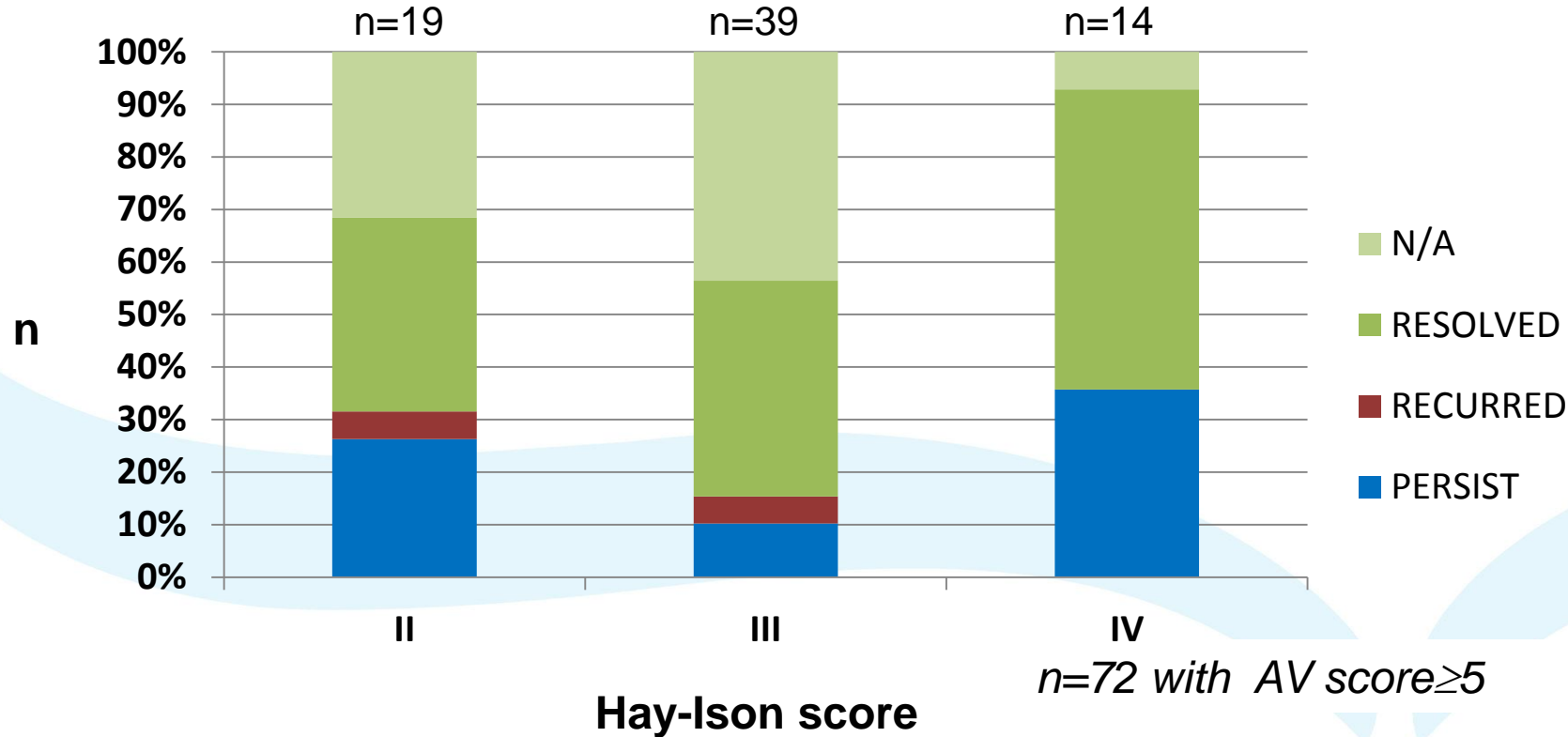


n=72 with AV score ≥ 5

Outcomes by AV score



Outcomes by Hay-Ison grade



Clinical implications

- About 5% of symptomatic women attending our service have a significantly abnormal AV score. Of these:
 - Half have classical BV by Hay-Ison score grade III
 - 25% have persistent or recurrent symptoms
 - Recurrence is associated with Hay-Ison grades II and IV and AV scores of 5-6
- Severe AV is seen in an older cohort
- AV scoring can alert clinicians to think outside the 'BV box'

AV sc	Clinical present ⁿ	Clinical impression	Treatment	Outcome
7	Discharge, odour	AV and thrush	Clindamycin, fluconazole	AV & thrush improving
7	Vulval itch	AV	Clindamycin	Resolved
7	Discharge, irritation	?AV	Clindamycin	Resolved
7	PCB, dyspareunia	Atrophic vaginitis	Vagifem, lube	?AV not cause
7	Discharge	HSV type 2	Acyclovir	Unknown
7	Discharge , itch	AV/BV	Clindamycin	Resolved
7	Lesions, irritation	HPV, AV and BV	Clindamycin, imiquimod	Resolved
8	Discharge	BV	clindamycin, Balance active	Resolved
8	Vulval irritation	AV	clindamycin	Resolved later relapsed
9	Discharge, irritation	AV	clindamycin	Resolved
9	Discharge, irritation	AV	clindamycin	Resolved