

United Kingdom British association for sexual health and HIV national guideline for the management of epididymo-orchitis, 2020

International Journal of STD & AIDS

2021, Vol. 32(10) 884–895

© The Author(s) 2021

Article reuse guidelines:

sagepub.com/journals-permissions

DOI: 10.1177/09564624211003761

journals.sagepub.com/home/std

Mimie Chirwa¹ , Olubanke Davies², Sheena Castelino³, Mbiye Mpenge⁴, Farai Nyatsanza⁵, Gulshan Sethi³, Majid Shabbir⁶ and Michael Rayment⁷ 

Abstract

The British Association for Sexual Health and HIV (BASHH) UK guideline for the management of epididymo-orchitis has been updated in 2020. It offers advice on diagnostic tests, treatment and health promotion principles in the effective management of epididymo-orchitis. Empirical treatment should be started in patients with objective swelling and tenderness on testicular examination. First-line empirical treatment for sexually acquired epididymo-orchitis has changed to ceftriaxone 1g intramuscularly and doxycycline. Higher dose of ceftriaxone in line with the BASHH 2018 gonorrhoea guideline ensures effective treatment of strains with reduced susceptibility. Ofloxacin or doxycycline is recommended in patients with epididymo-orchitis probably due to non-gonococcal organisms (e.g. negative microscopy for gram-negative intracellular diplococci or no risk factors for gonorrhoea identified). Where *Mycoplasma genitalium* is tested and identified, treatment should include an appropriate antibiotic (e.g. moxifloxacin). If enteric pathogens are a likely cause (e.g. older patient, not sexually active, recent instrumentation, men who practice insertive anal intercourse, men with known abnormalities of the urinary tract or a positive urine dipstick for leucocytes and nitrites), ofloxacin and levofloxacin are recommended. A clinical care pathway has been produced to simplify the management of epididymo-orchitis. A patient information leaflet has been developed.

Keywords

Bacterial disease, viral disease, protozoal disease, parasitic disease, other

New in the 2020 guideline

Aetiology

1. Tuberculous epididymo-orchitis following Bacillus Calmette-Guerin (BCG) bladder instillation for bladder cancer.
2. Consideration of non-infective pathologies such as vasculitis and rare infections such as brucella as indicated in the clinical history.

Further investigations

1. Brucella serology should be considered in patients from a brucellosis endemic area.
2. Colour duplex ultrasonography is not reliable enough to make a diagnosis of testicular torsion in all settings as it has a user-dependent false negative rate. It is recommended that patients with suspected clinical torsion should undergo an urgent exploration of the testis.

¹ Genitourinary Medicine, Bedfordshire Hospitals NHS Foundation Trust, Luton, UK

² Genitourinary Medicine, Epsom & St Helier University Hospitals NHS Trust, London, UK

³ Genitourinary Medicine, Guy's & St Thomas' Hospitals NHS Foundation Trust, London, UK

⁴ Consultant Microbiologist, Weston Area Health NHS Trust, Weston-super-Mare, Somerset, UK

⁵ Genitourinary Medicine, Cambridge Community Services NHS Trust, Cambridgeshire, UK

⁶ Urologist, Guy's & St Thomas' Hospitals NHS Foundation Trust, London, UK

⁷ Genitourinary Medicine, Chelsea and Westminster Hospital NHS Foundation Trust, London, UK

Corresponding author:

Mimie Chirwa, Genitourinary Medicine, Bedfordshire Hospitals NHS Foundation Trust, Luton and Dunstable University Hospital, Lewsey Road, Luton LU4 0DZ, UK.

Email: mkariuki@doctors.org.uk

Treatment

1. First-line empirical treatment for epididymo-orchitis most probably due to any sexually transmitted pathogen is now with ceftriaxone 1g intramuscularly and doxycycline 100 mg twice daily for 14 days.
2. Consideration of 1g ceftriaxone intramuscularly + ofloxacin 200 mg twice daily for epididymitis likely caused by sexually transmitted chlamydia and gonorrhoea and enteric organisms.
3. Consideration of ofloxacin 200 mg twice daily or levofloxacin 500 mg once daily for epididymo-orchitis most probably due to enteric pathogens.
4. Where *Mycoplasma genitalium* has been tested and identified, treatment should be guided to include an appropriate antibiotic (e.g. moxifloxacin).

Sexual partners

Sexual partners should be tested for other sexually transmitted infections (STIs) including HIV testing and given treatment with antibiotics to cover *C. trachomatis* and *N. gonorrhoeae* if confirmed in the index patient.

Follow-up

Uropathogen confirmed epididymo-orchitis is an indication for urology referral in order to exclude structural abnormalities/urinary tract obstruction.

Scope and purpose

The main objective of these guidelines is to offer recommendations on the diagnostic tests, treatment and health promotion principles in the effective management of epididymo-orchitis.

It is aimed primarily at the care of people aged 16 years or older presenting to healthcare professionals, working in departments offering level 3 care in STI management within the United Kingdom. However, the principles of the recommendations could be adopted at all levels.

Rigour of development

The British Association for Sexual Health and HIV (BASHH): 2015 framework for guideline development and assessment (https://www.bashhguidelines.org/media/1176/2015-guidelines-framework_updated-may-2018.pdf) was used to develop these guidelines. A MEDLINE search was performed for 2009–2017 using the keywords ‘epididymitis’, ‘orchitis’ and ‘epididymo-orchitis’. The Cochrane Database of Systematic Reviews and the Cochrane Controlled Trials Register up to 2017 were reviewed using the same keywords. Conference abstracts for British Association of Sexual Health and HIV, Federation of Infection

Societies and urology conferences were reviewed as were guidelines from Centers for Disease Control and Prevention, European Association of Urology and International Union against Sexually Transmitted Infection guidelines. Further references from articles identified were included. Article titles and abstracts were reviewed and full texts of relevant articles were reviewed. Meta-analyses of randomised controlled trials (RCTs) were done; RCTs and systematic reviews were prioritised and recommendations were made and graded based on the best evidence available.

A patient representative was recruited from a London sexual health clinic. They were involved in the development of the first and later drafts of the guideline as well as the patient information leaflet.

An equality impact assessment was undertaken and is published on the BASHH website.

Prior to publication, the guideline was appraised using AGREE II by CEG and then placed on the BASHH website for a 2-month consultation period inviting all BASHH members to submit comments to the CEG. The guideline was also reviewed by the BASHH Public Panel.

This guideline will be updated no later than 5 years after publication.

Introduction

Acute epididymo-orchitis is a clinical syndrome consisting of pain, swelling and inflammation of the epididymis +/- testis. Epididymitis may occur alone, as may orchitis (swelling of the testis). Throughout this guideline, the term epididymo-orchitis tends to be adopted, and the terms epididymo-orchitis, orchitis and epididymitis may be considered interchangeable. This may result from infectious and non-infectious pathologies. The most common route of infection is local extension and is mainly due to infections spreading from the urethra (sexually transmitted pathogens) or the bladder (urinary pathogens).

Aetiology

Bacterial

1. Under 35 years – most often a sexually transmitted pathogen such as *Chlamydia trachomatis* and *Neisseria gonorrhoeae*.^{1–12}
2. Over 35 years – most often non-sexually transmitted gram-negative enteric organisms causing urinary tract infections.^{1–12} Particular risks include recent instrumentation (such as prostatic biopsy and vasectomy) or catheterisation.^{13–16}
3. There is crossover between these groups and complete sexual history taking is imperative.^{3,7–9,11,12}
4. Men who engage in insertive anal intercourse are at risk of epididymo-orchitis secondary to sexually transmitted enteric organisms.^{1,17,18}

- Abnormalities of the urinary tract such as anatomical or functional abnormalities are common in the group infected with gram-negative enteric organisms. Approximately 20% of male cases with anorectal malformations (ARM) develop epididymo-orchitis.¹⁹ In cases of suspected epididymo-orchitis with a history of ARM, a recto-urinary communication or neurogenic bladder following anoplasty should be considered.^{19,20}
- All patients with a confirmed urinary tract pathogen should have further investigations of the urinary tract.^{21,22}
- Ureaplasma urealyticum* is found in men with epididymo-orchitis, often in association with *N. gonorrhoeae* or *C. trachomatis* infection. Evidence supporting it as a common cause of epididymo-orchitis is lacking.^{5,12,23}
- Mycoplasma genitalium* is a slow-growing microorganism, replicating intracellularly and extracellularly and able to establish latent or chronic infections.²⁴ An association with epididymitis is biologically plausible. It has been identified in some cases of epididymo-orchitis but evidence for its role in development of epididymo-orchitis is so far lacking.^{23,25}
- There has been a reported case of Pantone–Valentine leukocidin positive strain of *Staphylococcus aureus* in a healthy individual presenting with scrotal pain with folliculitis and superficial abscesses.²⁶

Viral

- Mumps is a notifiable disease which should be considered as an aetiology since the epidemic in 2005.²⁷ This epidemic mainly affected non-immunised adults born between 1982 and 1986. This complication of mumps (presenting with unilateral or bilateral orchitis) can occur in up to 40% of post-pubertal men.^{28–30}
- Other viral pathogens such as adenovirus and enterovirus have been reported in children, presumed to be a result of post-viral inflammation of the epididymis. This is a self-limiting condition.³¹

Granulomatous

- Extrapulmonary tuberculosis represents 40–45% of TB cases in the United Kingdom,³² but tuberculous epididymo-orchitis is a rare presentation. It is likely to present in patients from high prevalence countries or with a previous history of tuberculosis and particularly in patients with immunodeficiency.^{33,34} It is usually as a result of disseminated infection and commonly associated with renal TB but can be an isolated finding.^{33–35} Tuberculous epididymitis has also been increasingly reported as a complication of BCG instillation for treatment of bladder carcinoma.^{36,37}

Other infective causes

- Rare infective causes include brucella, fungi such as candida,³⁸ and schistosomiasis.³⁹
- Brucellosis should be considered in patients from endemic areas⁴⁰ such as the Mediterranean countries of Europe, North and East Africa, the Middle East, South and Central Asia and Central and South America. In non-endemic countries, diagnostic suspicion should be raised in the context of travel history to an endemic area, failure to respond to first-line antimicrobial therapy and/or a history of preceding fever, lethargy and night sweats.⁴¹

Non-infective causes

- 12–19% of men with Behcet's disease develop epididymo-orchitis. This is non-infective and thought to be part of the disease process. It is associated with more severe disease.⁴²
- Unilateral and bilateral epididymo-orchitis has also been reported as an adverse effect of amiodarone treatment and will resolve once treatment is ceased.^{43,44}
- Epididymo-orchitis is a rare manifestation of Henoch–Schönlein purpura (the commonest vasculitic disease in children).^{45–48}
- Other rare non-infective causes include familial Mediterranean fever⁴⁹ and polyarteritis nodosa.^{50,51}

Clinical features

- Patients with epididymo-orchitis typically present with acute onset unilateral scrotal pain, swelling and erythema.⁵²
- Patients may complain of symptoms of urethritis or urethral discharge but these symptoms may be absent.^{8,9,12,53} In addition, they may have symptoms in keeping with a urinary tract infection such as fever, dysuria, frequency and urgency.
- Testicular torsion (torsion of the spermatic cord) is the most important differential diagnosis. This is a surgical emergency that should be considered first in all patients, particularly young men, as testicular salvage is required within 6 hours and success diminishes with time.^{54–56} Testicular torsion occurs most commonly in the neonatal period and around puberty; however, it can occur at any age. The pain is typically sudden, occurring within hours and is usually severe in nature.^{55–57} The pain can radiate to the groin or lower abdomen and is often associated with nausea and vomiting. Patients may also report similar pain that improved without intervention in the past (intermittent torsion). In torsion, the testis is typically more tender than the epididymis, and the torted testis is often swollen and high riding with a horizontal position. However, none of these symptoms may be present and there are no completely reliable specific

clinical signs of torsion. Preliminary tests tend not to show urethritis or urinary tract infection.^{55,56} If a diagnosis of epididymo-orchitis can be clearly made, then the case should be treated as such. However, if there is any doubt of the cause of the acutely painful and swollen testis, torsion should be considered until proven otherwise.

Disease specific features

1. Tuberculosis: Symptoms suggestive of this include subacute/chronic onset of painless or painful scrotal swelling (epididymis first) which may or may not be associated with systemic symptoms of tuberculosis, scrotal sinus and thickened scrotal skin.^{33,35}
2. Mumps: Symptoms suggestive of this include headache and fever occurring before unilateral or bilateral parotid swelling. Patients may develop unilateral testicular swelling 7–10 days later which may present with epididymitis.⁵⁸ Mumps orchitis can occur without systemic symptoms.⁵⁹

Signs

1. The presence of palpable unilateral firm swelling and tenderness of the epididymis usually starting with the tail at the lower pole of the testis and spreading towards the whole epididymis and testis should prompt treatment.²
2. There may also be:
 - urethral discharge,
 - hydrocoele,
 - erythema+/-oedema of the scrotum,
 - pyrexia and
 - patients with testicular pain post-vasectomy may present with a tender unilateral fullness of the epididymis. In the absence of any other infective signs or symptoms, confirmation of an infective element should be sought before giving antibiotics in this scenario (refer to [Figure 1](#)).

Complications

1. Complications are more often seen in patients with uropathogen-related epididymo-orchitis than sexually transmitted infection-associated epididymo-orchitis.⁶⁰ These include
 - reactive hydrocoele,
 - abscess formation and infarction of the testicle (a rare complication) and⁶¹
 - infertility: the relationship between fertility and epididymo-orchitis is poorly understood. Mumps orchitis can lead to testicular atrophy in 30–50% of patients.⁶² Of those with bilateral orchitis, 13% will have reduced infertility.^{62,63}

Diagnosis

Epididymo-orchitis is a clinical diagnosis that is presumptively made based on presenting history, risk of STIs, physical examination findings and preliminary investigations ([Table 1](#)). A sexually transmitted cause should always be excluded. Suggested preliminary, laboratory and further investigations (and corresponding GRADE recommendations to do so) are presented in [Tables 1–3](#) respectively.

1. *Brucella* epididymo-orchitis has been reported in up to 20% of patients with brucellosis and therefore should be considered in a patient from a brucellosis endemic area presenting with epididymo-orchitis. Diagnosis is confirmed by brucella serology (IgM and IgG).⁷⁶
2. Non-infectious causes of epididymitis are usually evident from the history, for example, history of amiodarone use or underlying vasculitis, and are confirmed by negative tests for bacterial infection. Idiopathic epididymitis is a diagnosis of exclusion.⁶⁵
3. There is no role for epididymal aspiration/fine needle aspiration cytology in routine clinical practice. It may be useful in recurrent infection which fails to respond to therapy and if epididymo-orchitis is found at operation¹⁴ and in the case of suspected tuberculous epididymitis.^{75,77}

Management

General advice

1. Patients should be given advice on duration of symptoms, potential causes of epididymo-orchitis and possible long-term complications for themselves and their partners. This can be reinforced by giving them a patient information leaflet ([Supplemental Figure](#)).
2. Patients should be advised to abstain from sexual intercourse until they and their partner have completed treatment and follow-up in those with confirmed and suspected sexually transmitted infection.^{1,78}
3. Analgesia, rest and scrotal support are recommended.^{79–81} Scrotal support may be purchased from retailers. Non-steroidal anti-inflammatory medications may be of benefit if not contraindicated (**1A**).
4. An ultrasound of the scrotum should be considered if there is uncertainty about the clinical diagnosis or need to exclude associated complications (hydrocoele, abscess and infarction).
5. All patients with probable STI should be advised to attend an appropriate sexual health (GU) clinic for STI testing. When antimicrobials are commenced in non-GU settings, a FPU for *C. trachomatis* and *N. gonorrhoeae* NAAT testing and urine dipstick/MSU should be performed and *N. gonorrhoeae* culture if locally available to enhance the chance of isolating the causative pathogen.

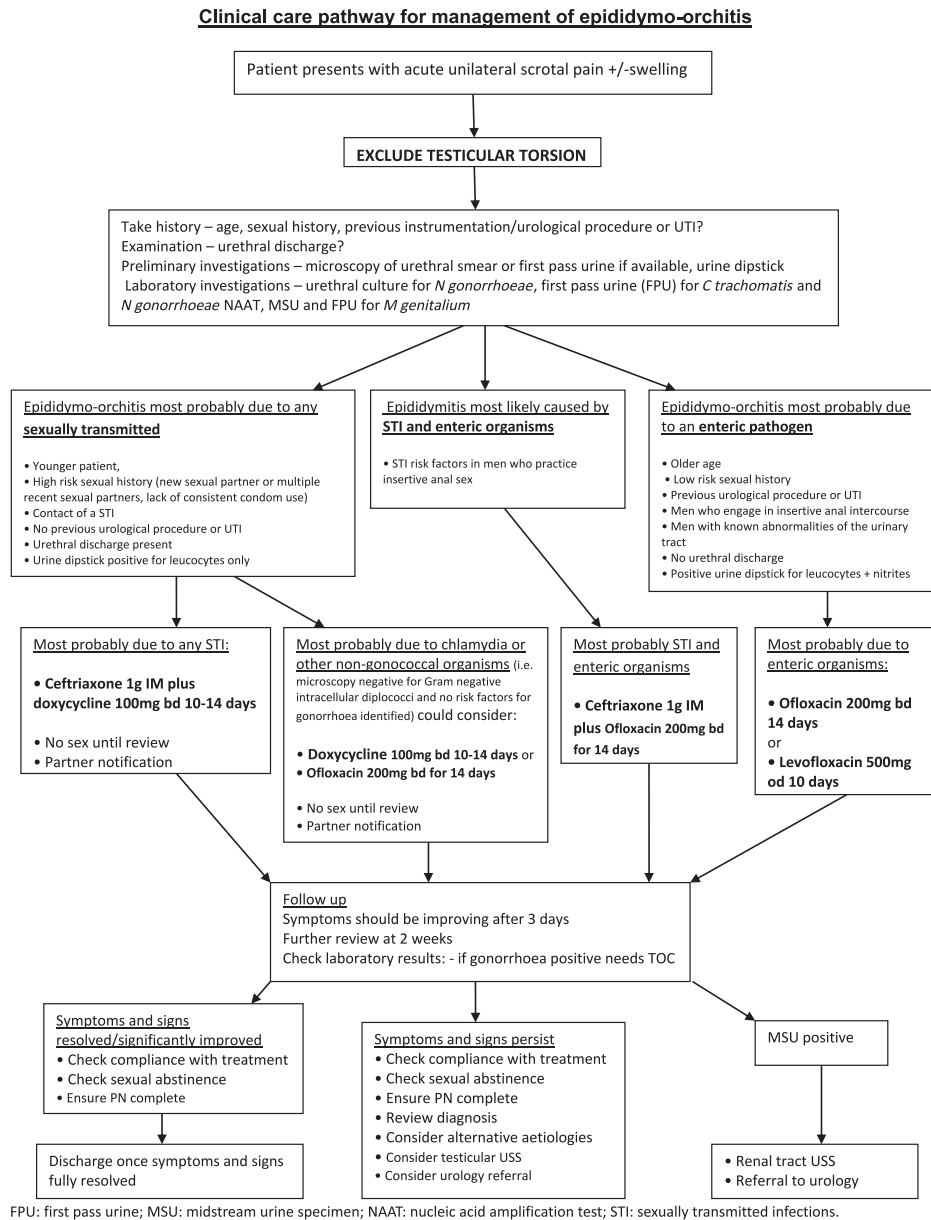


Figure 1. Clinical care pathway for management of epididymo-orchitis.

Treatment

Empirical treatment for epididymo-orchitis should be started in patients with objective swelling and tenderness on testicular examination.

Empirical therapy should be given to all patients with epididymo-orchitis at the time of the visit before all culture or NAAT results are available.

The antibiotic regimen chosen should be determined in light of the immediate tests (urethral smear and urinalysis). Age, history of insertive anal intercourse, recent prostate

biopsy, vasectomy, urinary tract instrumentation or catheterisation and any known urinary tract abnormalities in the patient should be considered.

Antibiotics used for sexually transmitted pathogens may need to be varied according to local knowledge of antibiotic sensitivities.

Recommended Regimens

For epididymo-orchitis most probably due to any sexually transmitted pathogen (e.g. younger patient, a new sexual

Table 1. Preliminary investigations.

| Test | Result |
|--|--|
| Gram stain of urethral smear ⁶⁴ | |
| Gram stain of urethral swab taken prior to micturition is highly sensitive and specific for documenting urethritis and the presence or absence of gonococcal infection. ⁶⁵ (IA) | Microscopy: ≥ 5 polymorphonuclear leucocytes (PMNLs) per high power field (HPF) × 1000 ^{2,65} Presence of intracellular gram-negative diplococci ⁶⁵ |
| Urine dipstick test ⁶⁶ | |
| If dipstick testing of the first pass urine (FPU) is positive for leucocyte esterase, it is suggestive of urethritis and lower UTI. ⁶⁵ (IB) | Positive leucocyte esterase test ⁶⁶ |
| The presence of nitrite and leucocyte esterase suggests UTI in men with urinary symptoms. ^{67,68} (IB) This combination demonstrated 84% specificity and a negative predictive value of 96% in one study of 8587 patients. ⁶⁹ | |
| A negative dipstick test should not exclude the diagnosis of UTI. ^{67,68} (IC) | |
| In one study, a urine dipstick for nitrites and leucocytes showed a sensitivity and specificity for a UTI of 83% and 90%, respectively, in the setting of non-gonococcal urethritis. ⁷⁰ | |
| Gram stain of spun down sample from FPU ² | |
| Confirms initial urine dipstick test result (2C) . This may not be possible in the majority of laboratories as centrifuges may not be available | Microscopy: ≥10 PMNLs per HFP × 1000 ^{2,65} |

Table 2. Laboratory investigations^{2,65}.

| Test | Result |
|---|--|
| Midstream urine specimen (MSU) microscopy and culture (IA) | |
| Identifies non-gonococcal and non-chlamydial urinary pathogens | Isolate of causative organism |
| Urethral swab for culture | |
| Test takes several days to yield a result | Positive culture of <i>Neisseria gonorrhoeae</i> |
| FPU/urethral swab for nucleic acid amplification test (NAAT) for <i>Neisseria gonorrhoeae</i> and <i>Chlamydia trachomatis</i> | |
| FPU for <i>Mycoplasma genitalium</i> (<i>M. genitalium</i>) | |
| Consider testing for <i>Mycoplasma genitalium</i> infection (2D) | May be positive |
| Screening for other STIs including blood borne viruses | |
| Indicated in all patients with sexually transmitted epididymo-orchitis ⁷¹ | |
| Blood tests | |
| Full blood count/white blood cell count (WBC), C-reactive protein (CRP) and erythrocyte sedimentation rate (ESR) | WBC, CRP and ESR may be elevated |

partner or more than one sexual partner in the past year, lack of consistent condom use and a contact of a sexually transmitted infection)

1. ceftriaxone 1g intramuscularly single dose^{1,2,82–84} **(IA)** plus doxycycline 100 mg by mouth twice daily for 10–14 days.^{1,2,82,83} **(IA)**

If most probably due to chlamydia or other non-gonococcal organisms (e.g. where gonorrhoea has been ruled out by Gram stain and no risk factors for gonorrhoea identified¹)

1. doxycycline 100 mg by mouth twice daily for 10–14 days^{3,12} **(IA)** or

2. ofloxacin² 200 mg by mouth twice daily for 14 days.^{7,85,86} **(IA)**

For epididymo-orchitis most probably due to an enteric pathogen (e.g. older patient, not sexually active, recent instrumentation (such as prostatic biopsy, vasectomy or catheterisation), men who practice insertive anal intercourse, men with known abnormalities of the urinary tract or positive urine dipstick for leucocytes and nitrites)

1. ofloxacin 200 mg by mouth twice daily for 14 days^{7,85,86} **(IA)** or
2. levofloxacin 500 mg by mouth once daily for 10 days^{1,2,87,88} **(2C)** and

Table 3. Further Investigations.

| Test | Result |
|---|---|
| <p>Colour duplex ultrasonography (CDU) (2B)</p> <p>CDU to assess arterial blood flow, may help differentiate between epididymo-orchitis and torsion of the spermatic cord.⁷²</p> <p>CDU may help confirm the diagnosis of epididymo-orchitis and exclude the development of common complications, including infarction, reactive hydrocoele and abscess formation.⁶⁵</p> <p>However, CDU is not reliable enough to make a diagnosis of testicular torsion in all settings as it has a user-dependent false negative rate.⁷³ In expert hands, high-resolution ultrasonography can detect torsion with more accuracy with a reported sensitivity of 97.3% and specificity of 99%.⁷⁴ However, each missed diagnosis results in a non-viable testis. It is, therefore, recommended that patients with suspected clinical torsion should not undergo imaging in the acute setting, which may further delay diagnosis and definitive treatment, but should have an urgent scrotal exploration as this is the only situation with a reliable 100% diagnostic accuracy.</p> <p>Surgical exploration (1C)</p> <p>Is indicated in cases where testicular torsion cannot be confidently excluded⁶⁵</p> | <p>Epididymis is enlarged and hyperaemic, with a low-resistance monophasic arterial waveform pattern⁶⁵</p> <p>Oedematous epididymis with vascular congestion and evidence of surrounding inflammatory reaction, with no evidence of testicular torsion or other pathology [65]</p> |
| <p>Investigation for structural abnormalities and urinary tract obstruction by a urologist (1C)</p> <p>Indicated in all patients with urinary tract pathogen confirmed epididymo-orchitis.^{21,22} Investigation will usually include an ultrasound and CT scan of the renal tract and flexible cystoscopy.</p> <p>Investigations for suspected tuberculous epididymitis (ID)</p> <p>Three early morning urines for acid and alcohol-fast bacilli (AAFB)</p> <p>Intravenous urography</p> <p>Renal tract ultrasound scan</p> <p>Biopsy</p> <p>Chest X-ray: to look for co-existing respiratory disease [75]</p> <p>Mumps IgM/IgG serology and/or viral detection PCR, according to local protocol (1C)</p> <p>Indicated when mumps orchitis is suspected</p> <p>An oral fluid sample for PCR can be taken within 6 weeks of onset of symptoms. Advice on obtaining sample and testing kits are available from Public Health England (PHE).</p> | <p>May be positive</p> |

3. *if quinolones are contraindicated*: amoxicillin/clavulanate 625 mg by mouth three times daily for 10 days.⁸³ **(1A)**

For acute epididymitis most likely caused by sexually transmitted chlamydia and gonorrhoea and/or enteric organisms (men who practice insertive anal sex), consider

1. ceftriaxone 1g IM in a single dose^{84,87,88} plus ofloxacin 200 mg orally twice a day for 10 days.¹ **(1A)**

Where *M. genitalium* has been tested and identified, treatment should be guided to include an appropriate antibiotic (e.g. moxifloxacin 400 mg once daily for 14 days.⁸⁹ **(1D)**

Corticosteroids have been used in the treatment of acute epididymo-orchitis but have not been shown to be of benefit.^{90,91}

In those with severe epididymo-orchitis or features suggestive of bacteraemia, inpatient management of fluid and electrolyte balance is required. Intravenous broad-spectrum therapy directed towards coliforms and *Pseudomonas aeruginosa* should be considered – cefuroxime 1.5 g IV three times daily +/- gentamicin for 3–5 days – until fever subsides (in those with severe allergy to penicillin, suggest ciprofloxacin 500 mg twice daily for 7–10 days guided by clinical response).^{52,92,93}

Allergy: For epididymo-orchitis of all causes where the patient is allergic to cephalosporins and/or tetracyclines

1. ofloxacin 200 mg by mouth twice daily for 14 days.^{7,85,86} **(1A)**

Patients should be warned of possible adverse effects of treatment. Side effects include those outlined in Table 4, below.

In November 2018, the European Medicines Agency finalised a review of severe side effects of quinolones and confirmed that use should be restricted and not be used in the treatment of infections that may get better without treatment, non-bacterial infections, recurrent urinary tract infections, and mild-moderate bacterial infections where other commonly recommended antibiotics can be used [Ref: European medicines agency. <https://www.ema.europa.eu/documents/referral/>

[quinolone-fluoroquinolone-article-31-referral-disabling-potentially-permanent-side-effects-lead_en.pdf](https://www.ema.europa.eu/documents/referral/quinolone-fluoroquinolone-article-31-referral-disabling-potentially-permanent-side-effects-lead_en.pdf)].

It is the opinion of the working group that epididymo-orchitis is a strong enough indication for the use of quinolones but that the risks and benefits should be discussed with patients.

Patient information should describe severe side effects and advise patients to discontinue treatment at any sign of side effects involving muscles, tendons, joints and the nervous system. Quinolones should be avoided in patients who have had serious side effects with quinolones in the past and used with caution in certain populations including the elderly, patients with renal disease, post-transplant patients and patients on corticosteroids. Moxifloxacin is contraindicated in pregnant and lactating women, patients under the age of 18 years, patients with impaired liver function and patients on drugs that prolong the QT interval. For a full list of contraindications and precautions, please refer to the individual drug summary of product characteristics at <https://www.medicines.org.uk>.

Sexual partners

For patients with confirmed or suspected sexually transmitted epididymo-orchitis (*N. gonorrhoeae* or *C. trachomatis*), all partners potentially at risk should be notified and evaluated. They should be tested for other STIs including HIV testing and given treatment with antibiotics to cover *C. trachomatis* and *N. gonorrhoeae* if confirmed in the index patient.^{2,84,94} The duration of look back is arbitrary, as the incubation period for epididymo-orchitis is unknown. Four weeks is suggested on the basis of current chlamydia guidelines⁹¹ and 2 weeks or their last partner if longer ago for gonorrhoeae.⁸⁴

Follow-up

A review of cultures should be performed at 48–72 hours to rationalise therapy if required. If there is no improvement in the patient's condition after 3 days, the diagnosis should be reassessed and therapy re-evaluated. Further follow-up is recommended at 2 weeks to assess compliance with

Table 4. Side effects associated with recommended treatments.

| | Gastrointestinal disturbance | Liver enzyme derangement | Photosensitivity skin reaction | Tendonitis/tendon rupture |
|-------------------------|------------------------------|--------------------------|--------------------------------|---------------------------|
| Ceftriaxone | ✓ | ✓ | | |
| Doxycycline | ✓ | ✓ | ✓ | |
| Ofloxacin | ✓ | ✓ | ✓ | ✓ |
| Levofloxacin | ✓ | ✓ | ✓ | ✓ |
| Amoxicillin/clavulanate | ✓ | ✓ | | |

Avoid quinolones in people with a history of quinolone-related tendonitis or seizures as they are at increased risk of tendon rupture and convulsions with NSAIDs. Concomitant use of NSAIDs may induce convulsions and concomitant use of corticosteroids increases the risk of tendon damage **(1D)** (see <https://bnf.nice.org.uk/drug-class/quinolones-2.html>).

treatment, ensure completion of partner notification and to check for improvement of symptoms. If the patient tested positive for gonorrhoea, a test of cure should be performed. If the test of cure is done by culture, this should be performed at least 72 hours after completion of antimicrobial therapy. NAAT test of cure should be conducted one or 2 weeks after completion of treatment depending on assay used.⁹⁵ Follow-up may be done by telephone, but if the patient has persisting symptoms, arrangements should be made for clinical review.

Swelling and tenderness can persist after antimicrobial therapy is completed but should be significantly improved. Swelling will have completely resolved in >80% of men by 3 months.⁹⁶ Where there is little improvement, further investigations such as an ultrasound scan or surgical assessment should be considered. Uropathogen confirmed epididymo-orchitis is an indication for urology referral in order to exclude structural abnormalities/urinary tract obstruction.

Differential diagnoses to consider in these circumstances include testicular ischaemia/infarction,^{61,97} testicular/epididymal tumour,⁵² alternative infectious aetiologies such as tuberculosis, mumps or rarer infective/non-infective causes³⁸ and progression to an abscess.^{61,96}

Auditable outcomes

1. The preliminary and laboratory investigations (excluding blood tests for FBC, CRP and ESR), as recommended in the guidelines, should be performed (target 90%).
2. A recommended antibiotic regimen from the guidelines should be prescribed (target 97%).
3. Sexual partners of men with sexually transmitted epididymo-orchitis should be tested for STIs and given treatment with antibiotics to cover *C. trachomatis* and *N. gonorrhoeae* if confirmed in the index patient. The targets achieved should be as set in the gonorrhoea and chlamydia national guidelines.
4. A written action plan should be recorded for men who have not responded clinically to the initial course of antibiotics (target 80%).

Editorial independence

This guideline was commissioned and edited by the CEG of the BASHH, without external funding being sought or obtained.

Declaration of conflicting interests

The author(s) declared no potential conflicts of interest with respect to the research, authorship and/or publication of this article.

Funding

The author(s) received no financial support for the research, authorship and/or publication of this article.

ORCID iDs

Mimie Chirwa  <https://orcid.org/0000-0002-1874-7650>

Michael Rayment  <https://orcid.org/0000-0002-2434-0101>

Supplemental Material

Supplemental material for this article is available online.

Notes

1. Common risk factors for gonorrhoea are previous *N. gonorrhoeae* infection; known contact of gonorrhoea; presence of purulent urethral discharge; men who have sex with men and multiple recent sexual partners.
2. Ofloxacin treats *N. gonorrhoeae*, *C. trachomatis* and most uropathogens with good penetration into the prostate. However, it is not first-line treatment for *N. gonorrhoeae* due to high levels of bacterial resistance to quinolones.⁸⁴

References

1. Workowski KA and Bolan GA. Centers for disease control and prevention. Sexually transmitted diseases treatment guidelines 2015 [published correction appears in MMWR Recomm Rep. 2015 Aug 28;64(33):924]. *MMWR Recomm Rep* 2015; 64(RR-03): 1–137.
2. Street EJ, Justice ED, Kopa Z, et al. The 2016 European guideline on the management of epididymo-orchitis. *Int J STD AIDS* 2017; 28(8): 744–749.
3. Berger RE, Alexander ER, Harnisch JP, et al. Etiology, manifestations and therapy of acute epididymitis: prospective study of 50 patients. *J Urol* 1979; 121: 750–754.
4. Harnish JP, Berger RE, Alexander ER, et al. Aetiology of acute epididymitis. *Lancet* 1977; 1: 819–821.
5. Berger RE, Alexander ER, Monda GD, et al. Chlamydia trachomatis as a cause of acute "idiopathic" epididymitis. *N Engl J Med* 1978; 298: 301–304.
6. Kristensen JK and Scheibel JH. Etiology of acute epididymitis presenting in a venereal disease clinic. *Sex Trans Dis* 1984; 11: 32–33.
7. Melekos MD and Asbach HW. Epididymitis: aspects concerning etiology and treatment. *J Urol* 1987; 138: 83–86.
8. Hawkins DA, Taylor-Robinson D, Thomas BJ, et al. Microbiological survey of acute epididymitis. *Genitourin Med* 1986; 62: 342–344.
9. Mulcahy FM, Bignell CJ, Rajakumar R, et al. Prevalence of chlamydial infection in acute epididymo-orchitis. *Genitourin Med* 1987; 63: 16–18.
10. Grant JB, Costello CB, Sequeira PJ, et al. The role of Chlamydia trachomatis in epididymitis. *Br J Urol* 1987; 60: 355–359.
11. DeJong Z, Pontonnier F, Plante P, et al. The frequency of Chlamydia trachomatis in acute epididymitis. *Br J Urol* 1988; 62: 76–78.
12. Hoosen AA, O'Farrell N and Van den Ende J. Microbiology of acute epididymitis in a developing country. *Genitourin Med* 1993; 69: 361–363.
13. Beck AD and Taylor DE. Post-prostatectomy epididymitis. A bacteriological and clinical study. *J Urol* 1970; 104: 143–145.
14. Berger RE, Holmes KK, Mayo ME, et al. The clinical use of epididymal aspiration cultures in the management of

- selected patients with acute epididymitis. *J Urol* 1980; 124: 60–61.
15. Humphreys H and Speller DC. Acute epididymo-orchitis caused by *Pseudomonas aeruginosa* and treated with ciprofloxacin. *J Infect* 1989; 19: 257–261.
 16. Mitemeyer BT, Lennox KW and Borski AA. Epididymitis: a review of 610 cases. *J Urol* 1966; 95: 390–392.
 17. Berger R, Kessler D and Holmes KK. Etiology and manifestations of epididymitis in young men: correlations with sexual orientation. *J Infect Dis* 1987; 155: 1341–1343.
 18. Barnes R, Daifuku R, Roddy R, et al. Urinary tract infections in sexually active homosexual men. *Lancet* 1986; 1: 171–173.
 19. Zaccara A, Ragozzino S, Iacobelli BD, et al. Epididymo-orchitis and anorectal malformations: when and in whom? *Pediatr Surg Int* 2015; 31(3): 305–309.
 20. VanderBrink BA, Sivan B, Levitt MA, et al. Epididymitis in patients with anorectal malformations: a cause for urologic concern. *Int Braz J Urol: Official J Braz Soc Urol* 2014; 40(5): 676–682.
 21. Svend-Hansen H, Nielson P, Pedersen N, et al. The value of routine intravenous urography in acute epididymitis. *Int Urol Nephrol* 1997; 9: 245–248.
 22. Kaver I, Matzkin H, Braf ZF, et al. Epididymo-orchitis: a retrospective study of 121 patients. *J Fam Pract* 1990; 30: 548–552.
 23. Ito S, Tsuchiya T, Yasuda M, et al. Prevalence of genital mycoplasmas and ureaplasmas in men younger than 40 years-of-age with acute epididymitis. *Int J Urol* 2012; 19: 234–238.
 24. Taylor-Robinson D and Jensen JS. *Mycoplasma genitalium*: from chrysalis to multicolored butterfly. *Clin Microbiol Rev* 2011; 24(3): 498–514.
 25. Taylor-Robinson D. *Mycoplasma genitalium*: an update. *Int J STD and AIDS* 2002; 13: 145–151.
 26. Raychaudhuri M and Chew PR. A case of epididymitis associated with Panton–Valentine leukocidin staphylococcus aureus. *STI* 2012; 88(5): 355–356.
 27. Gupta RK, Best J and MacMahon E. Mumps and the UK epidemic 2005. *BMJ* 2005; 330: 1132–1135.
 28. Jequier AM. The microbiology of semen and infections of the male genital tract. In Jequier AM ed. *Male Infertility: A Guide for the Clinician*. Oxford: Blackwell Science, 2000, 254–273.
 29. Beard CM, Benson RC Jr, Kelalis PP, et al. The incidence and outcome of mumps orchitis in Rochester, Minnesota, 1935–1974. *Mayo Clin Proc* 1977; 52: 3–7.
 30. Anonymous A retrospective survey of the complications of mumps. *J R Coll Gen Pract* 1974; 24: 552–556.
 31. Somekh E, Gorenstein A and Serour F. Acute epididymitis in boys: evidence of a post-infectious etiology. *J Urol* 2004; 171: 391–394.
 32. Health Protection Agency. *Tuberculosis Case Reports by Site of Disease*. England, 1999–2007. www.hpa.org.uk.
 33. Viswaroop BS, Kekre N and Goplalkrishnan G. Isolated tuberculous epididymitis: a review of 40 cases. *J Postgrad Med* 2005; 51(2): 109–111.
 34. Kinnear N, Hoh I, Campillo P, et al. Tuberculous epididymo-orchitis masquerading as acute scrotum. *BMJ Case Rep* 2016; 2016: bcr2015214060.
 35. Ferrie BG and Rundle JS. Tuberculous epididymo-orchitis: a review of 20 cases. *Br J Urol* 1983; 55: 437–439.
 36. Harada H, Seki M, Shinojima H, et al. Epididymo-orchitis caused by intravesically instilled bacillus Calmette-Guérin: genetically proven using a multiplex polymerase chain reaction method. *Int J Urol* 2006; 13(2): 183–185.
 37. Demers V and Pellsers V. "BCGitis": a rare case of tuberculous epididymo-orchitis following intravesical bacillus Calmette-Guérin therapy. *J Radiol Case Rep* 2012; 6(11): 16–21.
 38. Hagely M. Epididymo-orchitis and epididymitis: a review of causes and management of unusual forms. *Int J STD and AIDS* 2003; 14: 372–378.
 39. Kazzaz BA and Salmo NAM. Epididymitis due to *Schistosoma haematobium* infection. *Trop geographical Med* 1974; 26(3): 333–336.
 40. Savasci U, Zor M, Karakas A, et al. Brucellar epididymo-orchitis: a retrospective multicenter study of 28 cases and review of the literature. *Trav Med Infect Dis* 2014; 12(6): 667–672.
 41. Moens AA, Vlaspolter F, Verlind J, et al. Epididymo-orchitis due to brucellosis: not only to be considered in endemic areas. Two cases for the price of three patients. *Urologia Internationalis* 2009; 82(4): 481–483.
 42. Cho YH, Jung J, Lee KH, et al. Clinical features of patients with Behcet's disease and epididymitis. *J Urol* 2003; 170: 1231–1233.
 43. Gasparich JP, Mason JT, Greene HT, et al. Amiodarone-associated epididymitis: drug-related epididymitis in the absence of infection. *J Urol* 1985; 133: 971–972.
 44. Van Erven L and Schaliq MJ. Amiodarone: an effective antiarrhythmic drug with unusual side effects. *Heart* 2010; 96: 1593–1600.
 45. Jauhola O, Ronkainen J, Koskimies J, et al. Clinical course of extrarenal symptoms in Henoch–Schönlein purpura: a 6-month prospective study. *Arch Dis Child* 2010; 95(11): 871–876.
 46. Sakanoue M, Higashi Y, Kawai K, et al. Henoch Schönlein purpura with epididymitis in an adult. *J Dermatol* 2011; 38(6): 620–622.
 47. Modi S, Mohan M and Jennings A. Acute scrotal swelling in Henoch-Schonlein purpura: case report and review of the literature. *Urol Case Rep* 2016; 6: 9–11.
 48. Güneş M, Kaya C, Koca O, et al. Acute scrotum in Henoch-Schönlein purpura: fact or fiction? *Turk J Pediatr* 2012; 54(2): 194–197.
 49. Eshel G, Zemer D and Bar-Yochai A. Acute orchitis in familial mediterranean fever. *Ann Intern Med* 1988; 109: 164–165.
 50. Garg K and Dawson L. Single organ variant of polyarteritis nodosa in epididymis. *J Cancer Res Ther* 2015; 11(3): 662.
 51. Coulomb M-A, Bagnères D, Rossi D, et al. Epididymitis: unusual presentation of periarteritis nodosa. *Progres en Urologie : J de l'Association Francaise d'urologie de la Societe Francaise D'urologie* 2010; 20(4): 311–313.
 52. Giesler WM and Krieger JN. *Epididymitis in Sexually Transmitted Diseases*. In: Holmes KK, Sparling PF, Stamm WE, et al. 4th Edition. McGraw Hill Medical, 2008, 1127–1146.
 53. Watson RA. Gonorrhoea and acute epididymitis. *Mil Med* 1979; 144: 785–787.
 54. Williamson RCN. Torsion of the testis and allied conditions. *Br J Surg* 1976; 63: 465–467.

55. Knight PJ and Vassey LE. The diagnosis and treatment of the acute scrotum in children and adolescents. *Ann Surg* 1984; 200: 664–673.
56. Dudley M. Assume nothing. *MPS Casebook* 2007; 15(3): 23. <http://www.medicalprotection.org/uk/casebook/september2007/casereports/assume-nothing>.
57. Jefferson RH. Critical analysis of the clinical presentation of acute scrotum: a 9 year experience at a single institution. *J Urol* 1997; 158: 1198–1200.
58. Wharton IP, Chaudhry AH and French ME. A case of mumps epididymitis. *Lancet* 2006; 367: 9511.
59. Nickel WR and Plumb RT. Mumps orchitis. In Harrison JH, Gittes RF, Perlmutter AD, et al., eds. *Campbells Urology*. 5th edition. Philadelphia: W.B. Saunders Co., 1986, 977–988.
60. Luzzi GA and O'Brien TS. Acute epididymitis. *BJU Int* 2001; 87: 747–755.
61. Rencken RK, du Plessis DJ and de Haas LS. Venous infarction of the testis – a cause of non-response to conservative therapy in epididymo-orchitis. A case report. *S Afr Med J* 1990; 78: 337–338.
62. Casella R, Leibundgut B, Lehmann K, et al. Mumps orchitis: report of a mini-epidemic. *J Urol* 1997; 158(6): 2158.
63. Dejuqc N and Jegou B. Viruses in the mammalian male genital tract and their effects on the reproductive system. *Microbiol Mol Biol Rev* 2001; 65: 208–231.
64. Swartz SL, Kraus SJ, Herrmann KL, et al. Diagnosis and etiology of nongonococcal urethritis. *J Infect Dis* 1978; 138(4): 445–454.
65. BMJ Best Practice. Acute epididymitis. Updated: June 2018. Available from: <https://bestpractice.bmj.com/topics/en-gb/186/diagnosis-approach> (Last accessed 29 September 2019).
66. Schmiemann G, Kniehl E, Gebhardt K, et al. The diagnosis of urinary tract infection: a systematic review. *Dtsch Arztebl Int* 2010; 107(21): 361–367.
67. Koeijers JJ, Kessels AG, Nys S, et al. Evaluation of the nitrite and leukocyte esterase activity tests for the diagnosis of acute symptomatic urinary tract infection in men. *Clin Infect Dis* 2007; 45(7): 894–896.
68. Etienne M, Pestel-Caron M, Chavanet P, et al. Performance of the urine leukocyte esterase and nitrite dipstick test for the diagnosis of acute prostatitis. *Clin Infect Dis* 2008; 46(6): 951–953; author reply 3.
69. Marques AG, Doi AM, Pasternak J, et al. Performance of the dipstick screening test as a predictor of negative urine culture. *Einstein* 2017; 15(1): 34–39.
70. Lueng A and Horner P. Urinary tract infection in patients with acute non-gonococcal urethritis. *Int J STD and AIDS* 2003; 13: 801–804.
71. Radcliffe KW, Flew S, Poder A, et al. European guideline for the organisation of a consultation for sexually transmitted infections. *Int J STD AIDS* 2012; 23(9): 609–612.
72. Weber DM, Rosslein R and Fliegel C. Color doppler sonography in the diagnosis of acute scrotum in boys. *Eur J Pediatr Surg* 2000; 10: 235–241.
73. Cimador M, DiPace MR, Castagnetti M, et al. Predictors of testicular viability in testicular torsion. *J Pediatr Urol* 2007; 3: 387–390.
74. Kalfa N, Veyrac C, Lopez M, et al. Multicenter assessment of ultrasound of the spermatic cord in children with acute scrotum. *J Urol* 2007; 177: 297.
75. NICE guideline: tuberculosis. Published: January 2016, Updated: September 2019. Available from: <https://www.nice.org.uk/guidance/ng33> (Last accessed September 2019).
76. Al-Tawfiq JA. Brucella epididymo-orchitis: a consideration in endemic area. *Int Braz J Urol* 2006; 32: 313–315.
77. Sah SP, Bhadani PR, Regmi R, et al. Fine needle aspiration cytology of tubercular epididymitis and epididymo-orchitis. *Acta Cytol* 2006; 50: 241–242.
78. Robinson AJ, Grant JB, Spencer RC, et al. Acute epididymitis: why patient and consort must be investigated. *Br J Urol* 1990; 66: 642–645.
79. Lapidis J, Herwig KR, Andeson EC, et al. Oxyphenbutazone therapy for mumps orchitis, acute epididymitis and osetitis pubis. *J Urol* 1967; 98: 528–530.
80. Herwig KR, Lapidis J and Maclean TA. Response of acute epididymitis to oxyphenbutazone. *J Urol* 1971; 106: 890–891.
81. Bonkat G, Bartoletti RR, Bruyère F, et al. *The 2019 Urological Infections Guidelines*. Arnhem, the Netherlands: EAU Guidelines Office.
82. Lazaro N. *Sexually Transmitted Infections in Primary Care*. Second Edition 2013. British Association for Sexual Health and HIV (BASHH). Available at <https://www.rcgp.org.uk/-/media/Files/CIRC/RCGP-Sexually-Transmitted-Infections-in-Primary-Care-2013.ashx?la=en> (Last accessed July 2020).
83. New Zealand Sexual Health Society. Epididymo-orchitis management guidelines september 2017. Available at: <http://www.nzshs.org/docman/guidelines/management-of-sexual-health-conditions/epididymo-orchitis/156-epididymo-orchitis-guideline/file> (Last accessed October 2017).
84. Fifer H, Saunders J, Soni S, et al. 2018 UK national guideline for the management of infection with neisseria gonorrhoeae. *Int J STD AIDS* 2020; 31(1): 4–15.
85. Weidner W, Schiefer HG and Garbe C. Acute non-gonococcal epididymitis. Aetiological and therapeutic aspects. *Drugs* 1987; 34 (suppl 1): 111–117.
86. Weidner W, Garbe C, Weissbach L, et al. Initial therapy of acute unilateral epididymitis using ofloxacin. I: clinical and microbiological findings (German). *Urologe-AusgabeA* 1990; 29: 272–276.
87. Pilatz A, Hossain H, Kaiser R, et al. Acute epididymitis revisited: impact of molecular diagnostics on etiology and contemporary guideline recommendations. *Eur Urol* 2015; 68(3): 428–435.
88. European Association of Urology. Urological infections: acute infective epididymitis. 2016. Available from: <https://uroweb.org/guideline/urological-infections/#3>.
89. Soni S, Horner P, Rayment M, et al. British association for sexual health and hiv national guideline for the management of infection with mycoplasma genitalium (2018). <https://www.bashhguidelines.org/media/1198/mg-2018.pdf>.
90. Moore CA, Lockett BL, Lennox KW, et al. Prednisolone in the treatment of acute epididymitis: a comparative study. *J Urol* 1971; 106: 578–580.

91. Berger RE. Acute epididymitis: etiology and therapy. *Semin Urol* 1991; 9: 28–31.
92. Grabe M, Bishop MC, Bjerklund-Johansen TE, et al. EAU Guidelines on Male Urinary Tract Infections 2008. Sepsis in urology. Antimicrobial therapy Chapter 7.6.2 p 74.
93. Dellinger RP, Levy MM, Rhodes A, et al. Surviving sepsis campaign: international guidelines for management of severe sepsis and septic shock: 2012. *Crit Care Med* 2013; 41(2): 580–637. doi: [10.1097/CCM.0b013e31827e83af](https://doi.org/10.1097/CCM.0b013e31827e83af)
94. Nwokolo NC, Dragovic B, Patel S, et al. 2015 UK national guideline for the management of infection with Chlamydia trachomatis. *Int J STD AIDS* 2016; 27(4): 251–267.
95. Wind CM, Schim van der Loeff MF, Unemo M, et al. Test of cure for anogenital gonorrhoea using modern RNA based and DNA-Based nucleic acid amplification tests: a prospective cohort study. *Clin Infect Dis* 2016; 62(11): 1348–1355. doi: [10.1093/cid/ciw141](https://doi.org/10.1093/cid/ciw141)
96. Pilatz A, Wagenlehner F, Bschiepfer T, et al. Acute epididymitis in ultrasound: results of a prospective study with baseline and follow-up investigations in 134 patients. *Eur J of Radiol* 2013; 82(12); e762.
97. Eisner DJ, Goldman SM, Petronis J, et al. Bilateral testicular infarction caused by epididymitis. *AJR Am J Roentgenol* 1991; 157: 517–519.